

Restoration of Elbow Flexion in Traumatic Upper Brachial Plexus Palsy in Adults: Outcome with Intraplexus Distal Nerve Transfers in 78 Patients

Restauração da flexão do cotovelo na paralisia traumática superior do plexo braquial em adultos: resultado com transferências intraplexuais distais em 78 pacientes

Mario G. Siqueira¹ Roberto S. Martins¹ Wilson Fagioni Junior¹ Luciano Foroni¹ Carlos Otto Heise^{1,2}

¹Peripheral Nerve Surgery Unit, Division of Functional Neurosurgery, Instituto de Psiquiatria, Faculdade de Medicina da Universidade de São Paulo, São Paulo, São Paulo, Brazil

²Division of Clinical Neurophysiology, Department of Neurology, Faculdade de Medicina da Universidade de São Paulo, São Paulo, São Paulo, Brazil

Address for correspondence Mario G. Siqueira, MD, PhD, Unidade de Cirurgia de Nervos Periféricos, Divisão de Neurocirurgia Funcional, Instituto de Psiquiatria, Faculdade de Medicina da Universidade de São Paulo, Rua Dr. Ovídio Pires de Campos 875, Cerqueira César, São Paulo – SP, Brasil, 05403-903 (e-mail: mgsiqueira@uol.com.br).

Arq Bras Neurocir 2018;37:285–290.

Abstract

Objective To present the functional outcomes of distal nerve transfer techniques for restoration of elbow flexion after upper brachial plexus injury.

Method The files of 78 adult patients with C5, C6, ± C7 lesions were reviewed. The attempt to restore elbow flexion was made by intraplexus distal nerve transfers using a fascicle of the ulnar nerve (group A, $n = 43$), or a fascicle of the median nerve (group B, $n = 16$) or a combination of both (group C, $n = 19$). The result of the treatment was defined based on the British Medical Research Council grading system: muscle strength $< M3$ was considered a poor result.

Results The global incidence of good/excellent results with these nerve transfers was 80.7%, and for different surgical techniques (groups A, B, C), it was 86%, 56.2% and 100% respectively. Patients submitted to ulnar nerve transfer or double transfer (ulnar + median fascicles transfer) had a better outcome than those submitted to median nerve transfer alone ($p < 0.05$). There was no significant difference between the outcome of ulnar transfer and double transfer.

Conclusion In cases of traumatic injury of the upper brachial plexus, good and excellent results in the restoration of elbow flexion can be obtained using distal nerve transfers.

Keywords

- ▶ brachial plexus palsy
- ▶ distal nerve transfers
- ▶ elbow flexion restoration

received
September 14, 2018
accepted
October 26, 2018

DOI <https://doi.org/10.1055/s-0038-1676533>.
ISSN 0103-5355.

Copyright © 2018 by Thieme Revinter Publicações Ltda, Rio de Janeiro, Brazil

License terms



Resumo

Objetivo Apresentar os resultados funcionais das técnicas de transferências de nervos para a restauração da flexão do cotovelo em lesões traumáticas superiores do plexo braquial.

Método Foram revisados os arquivos de 78 pacientes adultos com lesões de C5, C6, ± C7. Na tentativa de restaurar a flexão do cotovelo, foram realizadas transferência de nervos intraplexuais distais utilizando um fascículo do nervo ulnar (grupo A, $n = 43$), ou um fascículo do nervo mediano (grupo B, $n = 16$) ou uma combinação de ambos (grupo C, $n = 19$). Os resultados do tratamento com diferentes tipos de transferências de nervos foram definidos com base no sistema de graduação do British Medical Research Council: força muscular $< M3$ foi considerado como mau resultado.

Resultados A incidência global de bons/excelentes resultados com essas transferências de nervos foi de 80,7% e para as diferentes técnicas cirúrgicas (grupos A, B, C), foi de 86%, 56,2% e 100%, respectivamente. Pacientes submetidos à transferência do nervo ulnar ou à dupla transferência (transferência de fascículos ulnar + mediano) alcançaram melhor resultado que aqueles submetidos à transferência isolada de fascículo do nervo mediano ($p < 0,05$). Não houve diferença estatística significativa entre os resultados da transferência de fascículo do nervo ulnar e a transferência dupla.

Conclusão A transferência distal de nervos pode produzir resultados bons e excelentes na restauração da flexão do cotovelo em pacientes com lesão traumática do plexo braquial superior.

Palavras-chave

- ▶ paralisia do plexo braquial
- ▶ transferências distal de nervos
- ▶ restauração da flexão do cotovelo

Introduction

Restoration of elbow flexion is usually the first priority in the surgical treatment of traumatic brachial plexus injuries in adults.¹⁻³ The aim of the surgical reconstruction is to restore biceps muscle function and sometimes brachial muscle function as well, through musculocutaneous reinnervation. Several operative procedures have been described with this purpose, including the direct repair with nerve grafting using one or more nonavulsed roots as donors of regenerating axons, or nerve transfers using uninvolved adjacent nerves originating or not from the plexus. Despite the extensive experience gained in the last decades with those techniques, there is no consensus about the best strategy to restore elbow flexion. Recently, distal nerve transfers, initially indicated only for nerve root avulsion injuries, became popular for the treatment of postganglionic nerve injuries as well, but there is no prospective, randomized controlled trials comparing reconstruction with grafts or nerve transfers in the literature. The objective of this retrospective study is to present the outcomes and compare the results of different techniques of distal nerve transfer for restoration of elbow flexion in traumatic upper brachial plexus lesions in adults.

Materials and Methods

Over an eight-year period (from January 2004 to January 2012), 406 patients with closed traumatic brachial plexus injuries were operated in the Peripheral Nerve Surgery Unit of the Division of Functional Neurosurgery of the Medical School of Universidade de São Paulo, Brazil. Cases of

complete brachial plexus lesions, with late referral (more than 1 year after the lesion), with insufficient follow-up (less than 18 months), and cases lost during the follow-up were discarded. Patients submitted to nerve grafting, to neurolysis, and those submitted to late secondary procedures (muscle/tendon transfers) were discarded as well. A total of 78 patients with C5, C6, ± C7 lesions remained for comparative retrospective analysis. The typical lesion was a closed traction brachial plexus injury that failed to show progressive spontaneous improvement. Prior to the surgical reconstruction, the patients underwent a physical examination, electrodiagnostic studies, imaging studies (computed tomography myelography or magnetic resonance imaging) and intraoperative observation. The nerve transfers were performed when the C5 and C6 roots had been avulsed, or when the patient was referred more than 8 months after the injury. The time interval from the injury to brachial plexus reconstruction was always shorter than 1 year, and the surgeries were grouped as early (less than 6 months) and overdue (more than 6 months).

The attempt to restore elbow flexion was made by intraplexus distal nerve transfers using a fascicle of the ulnar nerve (group A) (▶ Fig. 1), or a fascicle of the median nerve (group B) (▶ Fig. 2) or a combination of both techniques (fascicles of median and ulnar nerves; group C) (▶ Fig. 3).

Postoperatively, the affected upper limb was immobilized in internal rotation with the elbow flexed at ninety degrees for three weeks, and after this time the patients were referred to rehabilitation. The postoperative follow-up consisted of clinical evaluations every 6 months after surgery, for a period of at least 18 months. In the final clinical evaluation, the result of the treatment was defined based on the British




Fig. 1 Operative view, left arm, medial surface. Transfer of a motor fascicle of the ulnar nerve, usually related to the flexor carpi ulnaris muscle, to the motor branch of the musculocutaneous nerve of the biceps muscle.




Fig. 2 Operative view, left arm, medial surface. Transfer of a motor fascicle of the median nerve, usually related to the flexor carpi radialis muscle, to the motor branch of the musculocutaneous nerve of the biceps muscle.

Medical Research Council (BMRC) grading system (which goes from M0 to M5). Elbow flexion strength \geq M3 (contraction with active movement of normal amplitude against gravity) was considered a good result. Muscle strength $<$ M3 was considered a poor result. The final outcome of the three treatment groups was compared.

The statistical analysis for group comparison was performed using the Fisher exact test. The Mann-Whitney U test was applied for the comparison of the surgical timing between patients with good and bad outcomes. The differences between the groups were considered significant when $p < 0.05$.

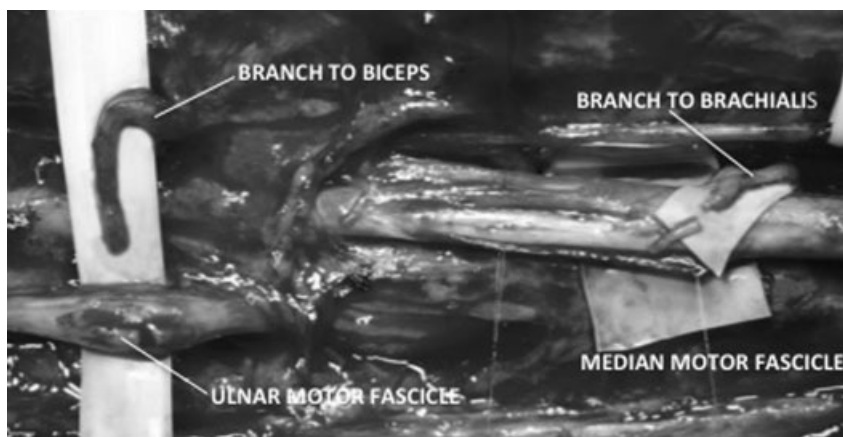


Fig. 3 Operative view, left arm, medial surface. Double transfer of a motor fascicle of the ulnar nerve to the motor branch of the musculocutaneous nerve of the biceps muscle, and of a motor fascicle of the median nerve to the motor branch of the musculocutaneous nerve of the brachialis muscle.

Results

Most of the patients were male (93.4%) with an average age of 28.7 years (range: 18 to 67 years). Motorcycle accidents were responsible for 79% of the injuries.

The donor nerves for intraplexus nerve transfers (78 patients; ▶ **Table 1**) included a fascicle of the ulnar nerve (group A: 43 patients), a fascicle of the median nerve (group B: 16 patients), and a combination of fascicles from the ulnar and median nerves (group C: 19 patients). The global incidence of good/excellent results with these nerve transfers was of 80.7%. For different surgical techniques (groups A, B and C) the percentage of good/excelente results was of 86%, 56.2% and 100% respectively. Patients submitted to ulnar nerve transfer or double transfer had a better outcome than those submitted to median nerve transfer alone ($p < 0.05$). There was no significant difference between the outcome of groups A and C. Patients with good outcomes were operated sooner than those with bad outcomes ($p < 0.05$), but there was no statistical difference regarding surgical timing among the groups.

Discussion

Adult brachial plexus paralysis is caused mainly by high velocity motor vehicle accidents and involves primarily young male adults.⁴ The socioeconomic impact of these injuries is usually high because the patients have to face a prolonged period of rehabilitation, and sometimes the final outcome is permanent paralysis. The functional outcome achieved with the surgical treatment of these patients has improved over the last decades, and the restoration of elbow flexion, an important function for daily activities, is the highest priority in the reconstruction. In our series, the reinnervation of the biceps muscle through the reconstruction of the musculocutaneous nerve was performed at the same time as the reinnervation of other targets, aiming to achieve as much of the entire plexus reconstruction as possible. The strategy we used to reconstruct the musculocutaneous nerve included the primary grafting and the transfer of intraplexus and extraplexus nerves. The choice of donor nerves for transfers relied on the severity of the

injury, the availability of motor donors, and surgeon preference. In partial lesions, primary grafting and intraplexus nerve transfers were used for the reconstruction of the musculocutaneous nerve. In complete lesions, primary grafting and extraplexus transfers were performed. The great boost in the surgical treatment of traumatic brachial plexus lesions came after the introduction of primary grafting with microsurgical techniques.^{2,5,6} Usually, a full exploration of the supraclavicular part of the plexus is performed to establish the extent and severity of the injury, and if any nerve roots are suitable for nerve graft repair. Even in complete clinical brachial palsies at least one root is available as a donor in many cases. The nerve grafts are usually coapted proximally to the C5 and/or C6 roots, and the distal coaptation can be in the upper trunk, the anterior division of the upper trunk, the lateral cord, or the musculocutaneous nerve itself, but the results with this approach are far from satisfactory. Data from the literature demonstrates that good/excellent results with primary grafting could be achieved in 10.4 to 92% of the patients (average = 66.2%).⁷⁻¹⁹ In the same period in which the data related to the intraplexus nerve transfers was collected from our series, we performed nerve grafting in 38 patients, connecting C5, C6 or both nerve roots to the upper trunk (2 cases), the upper trunk anterior division (24 cases), the lateral cord (3 cases), or directly to the musculocutaneous nerve (9 cases). Altogether, 23 patients (60.5%) achieved M3 or a higher degree of elbow flexion. Although some authors^{6,20-22} do prefer intraplexus donors (roots or trunks) for neurotization of the musculocutaneous nerve, the unsatisfactory results, the absence of a prospective, randomized clinical trial comparing nerve transfers versus nerve grafts, and a recent review demonstrating that in upper brachial plexus injuries nerve transfers are more successful for the restoration of elbow flexion than nerve grafting²³ motivated us to review our intraplexus transfer results.

The transfer of an ulnar nerve fascicle (usually related to the flexor carpi ulnaris muscle) to the motor branch of the musculocutaneous nerve of the biceps muscle was described by Oberlin et al,²⁴ and presents good/excellent results (M3 or higher) in the literature, ranging from 61.1 to 100% (average = 83.5%).^{9,18,24-37} We used this technique in 43

Table 1 Results of intraplexus nerve transfers

Results of Intraplexus Nerve Transfers					
Donor	Target	Cases	Good/excellent results (M3-M4)		
			Total	Surgery < 180 days before the lesion	Surgery > 180 days after the lesion
Ulnar motor fascicle	motor branch of the musculocutaneous nerve of the biceps muscle	43	37 cases/86%	17 cases/100%	20 cases/76.9%
Median motor fascicle	motor branch of the musculocutaneous nerve of the biceps muscle	16	9 cases/56.2%	5 cases/62.5%	4 cases/36.3%
Ulnar/median motor fascicles	motor branches of the musculocutaneous nerve of the biceps and brachialis muscles	19	19 cases/100%	6 cases/100%	13 cases/100%

patients, obtaining good/excellent results (M3 or higher) in 37 (86%) of them. The reinnervation of the biceps muscle using a fascicle of the median nerve (usually related to the flexor carpi radialis muscle) was described by Hou and Xu³⁸ in 2002 and by Sungpet et al³⁹ in 2003. The reported outcomes with this technique vary from 63.6 to 100% (average = 86.7%) of good/excellent results.^{27,38-40} Although some authors prefer this transfer to the procedure described by Oberlin because of the larger diameter of the median nerve and its proximity to the musculocutaneous nerve,⁴⁰ the incidence of good/excellent results in our series (9 patients out of 16; 56.2%) was inferior to the results using an ulnar fascicle. In an attempt to improve the results of the Oberlin procedure, a concomitant transfer of a fascicle of the median nerve to the motor branch of the musculocutaneous nerve of the brachialis muscle was introduced in 2003 by Tung et al.⁴¹ The published outcome of this technique ranges from 75 to 100% of good/excellent results (average = 93.4%).^{25,26,30,41-45} Two recent publications^{26,46} demonstrated that the intensity of the elbow flexion did not differ significantly between groups of patients treated with single (biceps) and double (biceps and brachial) muscle innervations; however, we achieved 100% of good/excellent results with the double transfer in this series. Although the results were better than median nerve transfers, there was no significant difference between double transfers and isolated ulnar nerve transfers.

Several factors may be related to better results in intraplexal distal nerve transfers when comparing them with supraclavicular brachial plexus grafting: two suture junctions in autogenous nerve grafting versus single suture junction in nerve transfer; in intraplexus nerve transfers, the coaptation between the donor and the target nerves is closer to the muscle to be innervated than in nerve grafting; grafts usually are not necessary in intraplexus transfers; albeit injured, the nerve transfer recipient is vascularized, while grafts are non-vascularized; the operative site is usually more fibrotic in the grafting procedure; in intraplexus nerve transfers, combinations of similarly behaving neuromuscular units facilitating the cortical adaptation are generally used.^{47,48}

The present study has some limitations. It is a retrospective series, and the number of patients is relatively small. Prospective randomized trials should certainly provide more definitive answers.

Conclusion

Our data showed acceptable outcomes, comparable to previously reported results in the literature. At the moment, intraplexus distal nerve transfers are our preferred strategy for the reinnervation of the biceps and sometimes the brachialis muscle as well.

References

- Alnot JY, Rostoucher P, Oberlin C, Touam C. [C5-C6 and C5-C6-C7 traumatic paralysis of the brachial plexus of the adult caused by supraclavicular lesions]. *Rev Chir Orthop Repar Appar Mot* 1998; 84(02):113-123(French)

- Millesi H, Meissl G, Katzer H. [Therapy of brachial plexus injuries. Proposal for an integrated therapy]. *Bruns Beitr Klin Chir* (1971) 1973;220(04):429-446(German)
- Narakas AO, Hentz VR. Neurotization in brachial plexus injuries. Indication and results. *Clin Orthop Relat Res* 1988;(237):43-56
- Faglioni W Jr, Siqueira MG, Martins RS, Heise CO, Foroni L. The epidemiology of adult traumatic brachial plexus lesions in a large metropolis. *Acta Neurochir (Wien)* 2014;156(05):1025-1028
- Luskin R, Campbell JB, Thompson WAL. Post-traumatic lesions of the brachial plexus: treatment by transclavicular exploration and neurolysis or autograft reconstruction. *J Bone Joint Surg Am* 1973; 55(06):1159-1176
- Narakas A. [Indications and results of direct surgical treatment in lesions caused by stretching of the brachial plexus. I. Indications for direct surgical treatment]. *Rev Chir Orthop Repar Appar Mot* 1977;63(01):88-106[French]
- Bertelli JA, Ghizoni MF. Results of grafting the anterior and posterior divisions of the upper trunk in complete palsies of the brachial plexus. *J Hand Surg Am* 2008;33(09):1529-1540
- Bertelli JA, Ghizoni MF. Reconstruction of complete palsies of the adult brachial plexus by root grafting using long grafts and nerve transfers to target nerves. *J Hand Surg Am* 2010;35(10):1640-1646
- Birch R. *Surgical Disorders of the Peripheral Nerves*. 2nd edition. London: Springer; 2011
- Chuang DCC, Epstein MD, Yeh MC, Wei FC. Functional restoration of elbow flexion in brachial plexus injuries: results in 167 patients (excluding obstetric brachial plexus injury). *J Hand Surg Am* 1993; 18(02):285-291
- Garg R, Merrell GA, Hillstrom HJ, Wolfe SW. Comparison of nerve transfers and nerve grafting for traumatic upper plexus palsy: a systematic review and analysis. *J Bone Joint Surg Am* 2011;93 (09):819-829
- Hentz VR, Narakas A. The results of microneurosurgical reconstruction in complete brachial plexus palsy. Assessing outcome and predicting results. *Orthop Clin North Am* 1988;19(01):107-114
- Kline DG, Hudson AR. *Nerve Injuries. Operative results for major nerve injuries, entrapments, and tumors*. Philadelphia: WB Saunders; 1995
- Lanaras TI, Schaller HE, Sinis N. Brachial plexus lesions: 10 years of experience in a center for microsurgery in Germany. *Microsurgery* 2009;29(02):87-94
- MacKinnon SE, Dellon AL. *Surgery of the Peripheral Nerve*. New York: Thieme; 1988
- Midha R. Stretch injuries to brachial plexus. In: Kim DH, Midha R, Murovic JA, Spinner RJ, eds. *Kline & Hudson's Nerve Injuries - Operative Results for Major Nerve Injuries, Entrapments, and Tumors*, 2nd ed. Philadelphia: Saunders-Elsevier; 2008:325-362
- Ochiai N, Nagano A, Sugioka H, Hara T. Nerve grafting in brachial plexus injuries. Results of free grafts in 90 patients. *J Bone Joint Surg Br* 1996;78(05):754-758
- Socolovsky M, Martins RS, Di Masi G, Siqueira M. Upper brachial plexus injuries: grafts vs ulnar fascicle transfer to restore biceps muscle function. *Neurosurgery* 2012;71(2, Suppl Operative) ons227-ons232
- Terzis JK, Papakonstantinou KC. The surgical treatment of brachial plexus injuries in adults. *Plast Reconstr Surg* 2000;106(05): 1097-1122, quiz 1123-1124
- Terzis JK, Vekris MD, Soucacos PN. Outcomes of brachial plexus reconstruction in 204 patients with devastating paralysis. *Plast Reconstr Surg* 1999;104(05):1221-1240
- Tonkin MA, Eckersley JR, Gschwind CR. The surgical treatment of brachial plexus injuries. *Aust N Z J Surg* 1996;66(01):29-33
- Vekris MD, Soucacos PN. Post-traumatic brachial plexus paralysis: current management of reconstruction. *Curr Orthop* 2001; 15:76-83
- Ali ZS, Heuer GG, Faught RWF, et al. Upper brachial plexus injury in adults: comparative effectiveness of different repair techniques. *J Neurosurg* 2015;122(01):195-201

- 24 Oberlin C, Béal D, Leechavengvongs S, Salon A, Dauge MC, Sarcy JJ. Nerve transfer to biceps muscle using a part of ulnar nerve for C5-C6 avulsion of the brachial plexus: anatomical study and report of four cases. *J Hand Surg Am* 1994;19(02):232-237
- 25 Barthel PY, Barbary S, Breton A, et al. [Recovery of elbow flexion in post-traumatic C5-C6 and C5-C6-C7 palsy: retrospective dual-center study comparing single and double nerve transfer]. *Chir Main* 2014;33(03):211-218[French]
- 26 Carlsen BT, Kircher MF, Spinner RJ, Bishop AT, Shin AY. Comparison of single versus double nerve transfers for elbow flexion after brachial plexus injury. *Plast Reconstr Surg* 2011;127(01):269-276
- 27 Cho AB, Paulos RG, de Resende MR, et al. Median nerve fascicle transfer versus ulnar nerve fascicle transfer to the biceps motor branch in C5-C6 and C5-C7 brachial plexus injuries: nonrandomized prospective study of 23 consecutive patients. *Microsurgery* 2014;34(07):511-515
- 28 Coulet B, Boretto JG, Lazerges C, Chammas M. A comparison of intercostal and partial ulnar nerve transfers in restoring elbow flexion following upper brachial plexus injury (C5-C6+/-C7). *J Hand Surg Am* 2010;35(08):1297-1303
- 29 Ferraresi S, Garozzo D, Buffatti P. Reinnervation of the biceps in C5-7 brachial plexus avulsion injuries: results after distal bypass surgery. *Neurosurg Focus* 2004;16(05):E6
- 30 Grondin RT, Durand S, Oberlin C. Fascicular nerve transfers to restore elbow flexion. In: Midha R, Zager ER, eds. *Surgery of Peripheral Nerves: A Case-Based Approach*. New York: Thieme; 2008:60-64
- 31 Leechavengvongs S, Witoonchart K, Uerpairojkit C, Thuvasethakul P, Ketmalasiri W. Nerve transfer to biceps muscle using a part of the ulnar nerve in brachial plexus injury (upper arm type): a report of 32 cases. *J Hand Surg Am* 1998;23(04):711-716
- 32 Loy S, Bhatia A, Asfazadourian H, Oberlin C. [Ulnar nerve fascicle transfer onto the biceps muscle nerve in C5-C6 or C5-C6-C7 avulsions of the brachial plexus. Eighteen cases]. *Ann Chir Main Memb Super* 1997;16(04):275-284 [French]
- 33 Sedain G, Sharma MS, Sharma BS, Mahapatra AK. Outcome after delayed Oberlin transfer in brachial plexus injury. *Neurosurgery* 2011;69(04):822-827, discussion 827-828
- 34 Sungpet A, Suphachatwong C, Kawinwonggowit V, Patradul A. Transfer of a single fascicle from the ulnar nerve to the biceps muscle after avulsions of upper roots of the brachial plexus. *J Hand Surg [Br]* 2000;25(04):325-328
- 35 Teboul F, Kakkar R, Ameur N, Beaulieu JY, Oberlin C. Transfer of fascicles from the ulnar nerve to the nerve to the biceps in the treatment of upper brachial plexus palsy. *J Bone Joint Surg Am* 2004;86-A(07):1485-1490
- 36 Vekris MD, Beris AE, Johnson EO, et al. Musculocutaneous neurotization to restore elbow flexion in brachial plexus paralysis. *Microsurgery* 2006;26(04):325-329
- 37 Venkatramani H, Bhardwaj P, Faruquee SR, Sabapathy SR. Functional outcome of nerve transfer for restoration of shoulder and elbow function in upper brachial plexus injury. *J Brachial Plex Peripher Nerve Inj* 2008;3:15
- 38 Hou Z, Xu Z. Nerve transfer for treatment of brachial plexus injury: comparison study between the transfer of partial median and ulnar nerves and that of phrenic and spinal accessory nerves. *Chin J Traumatol* 2002;5(05):263-266
- 39 Sungpet A, Suphachatwong C, Kawinwonggowit V. One-fascicle median nerve transfer to biceps muscle in C5 and C6 root avulsions of brachial plexus injury. *Microsurgery* 2003;23(01):10-13
- 40 Nath RK, Lyons AB, Bietz G. Physiological and clinical advantages of median nerve fascicle transfer to the musculocutaneous nerve following brachial plexus root avulsion injury. *J Neurosurg* 2006;105(06):830-834
- 41 Tung TH, Novak CB, Mackinnon SE. Nerve transfers to the biceps and brachialis branches to improve elbow flexion strength after brachial plexus injuries. *J Neurosurg* 2003;98(02):313-318
- 42 Bhandari PS, Sadhotra LP, Bhargava P, et al. Surgical outcomes following nerve transfers in upper brachial plexus injuries. *Indian J Plast Surg* 2009;42(02):150-160
- 43 Liverneaux PA, Diaz LC, Beaulieu JY, Durand S, Oberlin C. Preliminary results of double nerve transfer to restore elbow flexion in upper type brachial plexus palsies. *Plast Reconstr Surg* 2006;117(03):915-919
- 44 Mackinnon SE, Novak CB, Myckatyn TM, Tung TH. Results of reinnervation of the biceps and brachialis muscles with a double fascicular transfer for elbow flexion. *J Hand Surg Am* 2005;30(05):978-985
- 45 Ray WZ, Pet MA, Yee A, Mackinnon SE. Double fascicular nerve transfer to the biceps and brachialis muscles after brachial plexus injury: clinical outcomes in a series of 29 cases. *J Neurosurg* 2011;114(06):1520-1528
- 46 Martins RS, Siqueira MG, Heise CO, Foroni L, Teixeira MJ. A prospective study comparing single and double fascicular transfer to restore elbow flexion after brachial plexus injury. *Neurosurgery* 2013;72(05):709-714, discussion 714-715, quiz 715
- 47 Malessy MJ, Bakker D, Dekker AJ, Van Duk JG, Thomeer RT. Functional magnetic resonance imaging and control over the biceps muscle after intercostal-musculocutaneous nerve transfer. *J Neurosurg* 2003;98(02):261-268
- 48 Malessy MJ, Thomeer RT, van Dijk JG. Changing central nervous system control following intercostal nerve transfer. *J Neurosurg* 1998;89(04):568-574