

Case Report

Hemodynamic stroke caused by strangulation

Hugo Sterman Neto, Iuri Santana Neville, Andre Beer-Furlan, Wagner Malago Tavares, Manoel Jacobsen Teixeira, Wellingson Silva Paiva

Division of Neurosurgery, University of São Paulo Medical School, São Paulo, Brazil

Received August 3, 2014; Accepted August 28, 2014; Epub September 15, 2014; Published September 30, 2014

Abstract: We report a case of watershed ischemic stroke in a 36-year-old male secondary to manual strangulation. The patient presented with a right hemiparesis with grade IV motor deficit and an expressive aphasia. Radiological investigation revealed an ischemic stroke on the left distal middle cerebral artery territory and in watershed areas of the left anterior and posterior cerebral arteries. There was no evidence of injury of cervical vessels. The hemodynamic mechanism and associated brain injury secondary to manual strangulation is described and discussed based on a literature review.

Keywords: Strangulation, watershed, ischemic stroke

Introduction

Strangulation describes the process whereby an external force is applied to the neck that results in a depressed or complete loss of consciousness. The external force can be the use of the bare hands (manual), ligature (a cord-like object), and gravity (near-hanging). The manual strangulation is a common injury found in domestic violence [1, 2], in which the victim is almost always the woman.

Case reports and case series have been published [1, 3] in the literature describing symptoms [4], radiology in surviving patients [5], post-mortem examination [6], and different precipitating factors of the ischemic stroke [7-11] secondary to strangulation. However there are no reports that describe the low cerebral blood flow without apparent injury to large cervical vessels as the mechanism of brain injury.

We report a case of a patient who was victim of manual strangulation and presented with ischemic stroke due to low cerebral blood flow. The hemodynamic mechanism is described and occurrence of brain injuries secondary to manual strangulation is discussed based on a literature review.

Case report

After a group assault, a 36-year-old man was taken to the emergency department of a local

hospital. According to the rescue team report, the patient was attacked by 3 men and suffered manual strangulation.

He was transferred to our service, a high complexity trauma hospital, for medical evaluation and treatment after two days. The patient was admitted with normal and stable vital signs, with minor wounds on both arms. The neurological examination revealed a right hemiparesis with grade IV motor deficit and an incomplete expressive aphasia. It was noted a wound on the cervical region (zone II) with semicircular bruising, and lesions compatible with nail printing. Moreover, he had subconjunctival hemorrhage and bilateral periorbital ecchymosis (**Figure 1**). There was no dysphonia, dysphagia nor odynophagia.

The head computed tomography (CT) showed hypoattenuation in cortical and subcortical areas of the left cerebral hemisphere compatible with watershed infarct. It also showed fracture of the left orbital floor and an intact hyoid bone (**Figure 2**).

The investigation was complemented with magnetic resonance imaging (MRI) of the brain about 20 days after the trauma, which showed restriction on diffusion weighted imaging of the left distal middle cerebral artery territory and in watershed areas of the left anterior and poste-

Hemodynamic stroke caused by strangulation

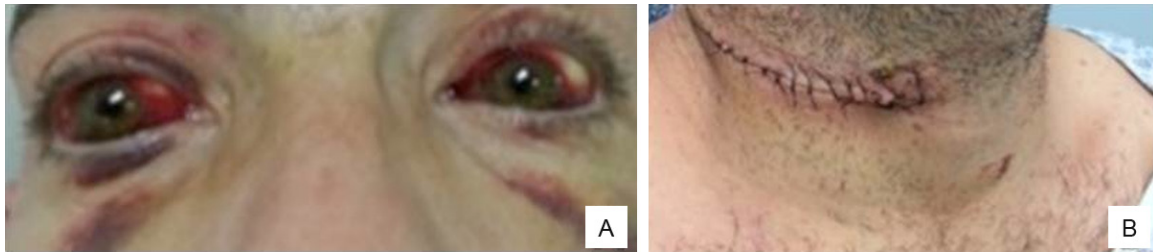


Figure 1. Photography of the patient showing in (A) Subconjunctival hemorrhage and bilateral periorbital ecchymosis. In (B) Wound on the cervical region (zone II) with semicircular bruising, and lesions compatible with nail printing.

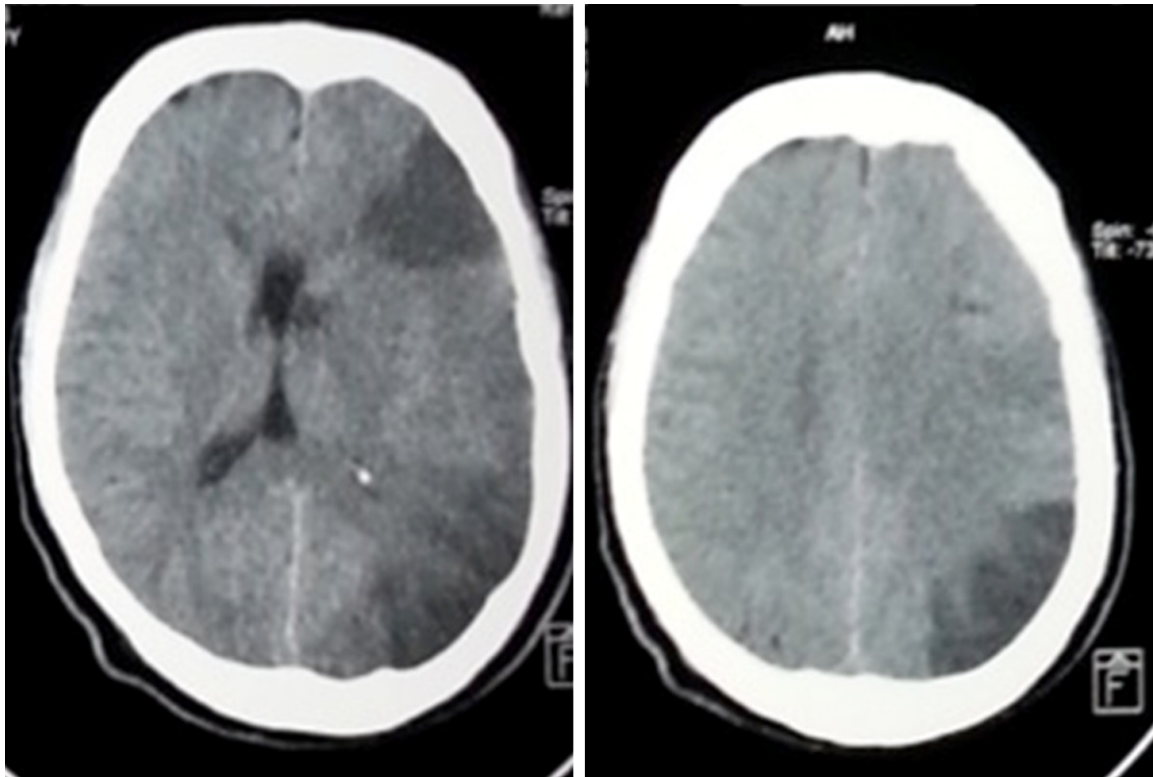


Figure 2. The head computed tomography (CT) showed hypoattenuation in cortical and subcortical areas of the left cerebral hemisphere compatible with watershed infarct.

rior cerebral arteries, confirming the findings of subacute ischemic stroke.

A Doppler ultrasound and angiography of the extracranial carotid and vertebral arteries was done due to the mechanism of injury, and showed no abnormalities. Cardiovascular evaluation with electrocardiography, chest radiography and transthoracic echocardiography excluded comorbidities that could have contributed to the occurrence of cerebral ischemic injury.

After completion of the investigation, the patient remained neurologically stable with a grade IV motor deficit and improvement of the expres-

sive aphasia. He was discharged to outpatient rehabilitation clinic.

Discussion

Asphyxia is defined as a syndrome resulting from the absence or low concentration of oxygen in the air breathed, including any form of oxygen deprivation [12]. Strangulation is a mixed type of mechanical asphyxia, in which circulatory, ventilatory and nervous phenomena overlap. The use of bare hands as the instrument of compression of neck structures (vessels and airways) is defined as manual strangulation [12, 13].

The most frequent signs of manual strangulation are usually reported only in autopsies. Unfortunately, clinical findings are evident in approximately 50% of surviving patients [14]. Yen *et al.*, described the CT and MRI findings in patients who survived manual strangulation with ischemia or hemorrhage [5].

The mechanism of death in cases of constriction of the neck may involve several factors [15]: cardiac arrhythmia by compression of the carotid sinus, obstruction of blood flow by compression of the carotid arteries, obstruction of venous return and consequent congestion secondary to the jugular veins compression, and obstruction of the airflow by compression of larynx. There may be some variables related to the way the force are applied to the neck: the area, the force magnitude, the duration and the region where force was applied [15]. However, the fatal outcome is almost always multifactorial. The classical sequence of events defined for death secondary to manual strangulation includes a mild cervical compression resulting in venous stasis and congestion associated with hypoxia due to loss of consciousness. This event leads to loss of cervical tone, ultimately causing arterial and airway obstruction (anoxic anoxia) and death [16]. There is also the arrhythmia caused by stimulation of the carotid sinus, which is observed in cases of sudden death [4, 17].

The literature indicates that brain damage may occur in survivors of manual strangulation in an acute or late onset. Among the causative factors of brain injury, the cervical carotid artery dissection with or without thrombosis is the most described mechanisms [7-9]. However, there are reports of patients with brain lesions without evidence of a cervical vascular abnormality. The lesions described include: brain death on post-mortem examination (hypoxic ischemic encephalopathy), ischemic and hemorrhagic stroke (embolic or occlusive etiology) and ischemic stroke lesions of the basal ganglia [11, 18].

To our knowledge, this is the first report that describes the hemodynamic mechanism without injury of large cervical vessels as the cause of brain injury. Our case showed signs suggestive of constriction of the neck (cervical bruising, and subconjunctival hemorrhage). In addition, the radiological features of ischemia sug-

gest that the low blood flow was responsible for the injury in this patient. The significant decrease in cerebral blood flow for an unknown period of time was sufficient to cause an irreversible brain injury. Considering that the investigation showed no vascular abnormalities, one could assume that the temporary arterial stenosis due to mechanical cervical compression was the most likely mechanism of injury.

Conclusion

Although there are reports of surviving patients with brain injury secondary to manual strangulation, this is the first report that describes the low cerebral blood flow (hemodynamic) without apparent injury to large cervical vessels as the mechanism of brain injury. The extrinsic constriction of the cervical carotid artery due to manual strangulation may result in decreased cerebral blood flow, causing ischemia in watershed areas of cerebral arteries.

Disclosure of conflict of interest

None.

Address correspondence to: Dr. Wellingson Paiva, Division of Neurosurgery, University of São Paulo Medical School, 470 Alves Guimarães St., Ap. 93, São Paulo-SP 05410-000, Brazil. E-mail: wellingson-paiva@yahoo.com.br

References

- [1] Shields LB, Corey TS, Weakley-Jones B, Stewart D. Living victims of strangulation: a 10-year review of cases in a metropolitan community. *Am J Forensic Med Pathol* 2010; 31: 320-5.
- [2] Wilbur L, Higley M, Hatfield J, Surprenant Z, Taliaferro E, Smith DJ Jr, Paolo A. Survey results of women who have been strangled while in an abusive relationship. *J Emerg Med* 2001; 21: 297-302.
- [3] Faugno D, Waszak D, Strack GB, Brooks MA, Gwinn CG. Strangulation forensic examination: best practice for health care providers. *Adv Emerg Nurs J* 2013; 35: 314-27.
- [4] Plattner T, Bolliger S, Zollinger U. Forensic assessment of survived strangulation. *Forensic Sci Int* 2005; 153: 202-7.
- [5] Yen K, Vock P, Christe A, Scheurer E, Plattner T, Schon C, Aghayev E, Jackowski C, Beutler V, Thali MJ, Dirnhöfer R. Clinical forensic radiology in strangulation victims: forensic expertise based on magnetic resonance imaging (MRI) findings. *Int J Legal Med* 2007; 121: 115-23.

- [6] Yen K, Thali MJ, Aghayev E, Jackowski C, Schweitzer W, Boesch C, Vock P, Dirnhofer R, Sonnenschein M. Strangulation signs: initial correlation of MRI, MSCT, and forensic neck findings. *J Magn Reson Imaging* 2005; 22: 501-10.
- [7] Clarot F, Vaz E, Papin F, Proust B. Fatal and non-fatal bilateral delayed carotid artery dissection after manual strangulation. *Forensic Sci Int* 2005; 149: 143-50.
- [8] Le Blanc-Louvry I, Papin F, Vaz E, Proust B. Cervical arterial injury after strangulation—different types of arterial lesions. *J Forensic Sci* 2013; 58: 1640-3.
- [9] Malek AM, Higashida RT, Halbach VV, Dowd CF, Phatouros CC, Lempert TE, Meyers PM, Smith WS, Stoney R. Patient presentation, angiographic features, and treatment of strangulation-induced bilateral dissection of the cervical internal carotid artery. Report of three cases. *J Neurosurg* 2000; 92: 481-7.
- [10] Jockers-Scherubl M, Vogel HP, Marx P. [Cerebral infarct caused by compression of the carotid artery in an alcohol intoxicated patient]. *Nervenarzt* 1993; 64: 401-3.
- [11] Sethi PK, Sethi NK, Torgovnick J, Arsura E. Delayed left anterior and middle cerebral artery hemorrhagic infarctions after attempted strangulation: a case report. *Am J Forensic Med Pathol* 2012; 33: 105-6.
- [12] França G. Traumatologia Médico-Legal. In: França G, editor. *Medicina Legal*. 9 ed. Rio de Janeiro: Guanabara Koogan; 2012. pp. 157-8.
- [13] Sauvageau A, Boghossian E. Classification of asphyxia: the need for standardization. *J Forensic Sci* 2010; 55: 1259-67.
- [14] McClane GE, Strack GB, Hawley D. A review of 300 attempted strangulation cases Part II: clinical evaluation of the surviving victim. *J Emerg Med* 2001; 21: 311-5.
- [15] Hawley DA, McClane GE, Strack GB. A review of 300 attempted strangulation cases Part III: injuries in fatal cases. *J Emerg Med* 2001; 21: 317-22.
- [16] Iserson KV. Strangulation: a review of ligature, manual, and postural neck compression injuries. *Ann Emerg Med* 1984; 13: 179-85.
- [17] Anscombe AM, Knight BH. Case report. Delayed death after pressure on the neck: possible causal mechanisms and implications for mode of death in manual strangulation discussed. *Forensic Sci Int* 1996; 78: 193-7.
- [18] Hori A, Hirose G, Kataoka S, Tsukada K, Furui K, Tonami H. Delayed postanoxic encephalopathy after strangulation. Serial neuroradiological and neurochemical studies. *Arch Neurol* 1991; 48: 871-4.