

Primary adenocarcinoma arising in esophageal colon interposition for corrosive esophageal injury: a case report and review of the literature



Authors

Diogo Turiani Hourneaux De Moura¹, Igor Braga Ribeiro¹, Martin Coronel¹, Eduardo Turiani Hourneaux De Moura¹, Joana Rita Carvalho², Elisa Ryoka Baba¹, Eduardo Guimarães Hourneaux De Moura¹

Institutions

- 1 Gastrointestinal Endoscopy Unit, Hospital das Clínicas da Faculdade de Medicina da Universidade de São Paulo, São Paulo, SP, Brazil
- 2 Department of Gastroenterology and Hepatology, North Lisbon Hospital Center, University of Lisbon, Portugal

Corresponding author

Igor Braga Ribeiro, MD, Av. Dr Enéas de Carvalho Aguiar, 225, 6o, andar, bloco 3, Cerqueira Cesar
ZIP Code 05403-010, São Paulo, SP, Brasil
Fax: +55112661-6467
igorbraga1@gmail.com

submitted 21.6.2018

accepted after revision 5.9.2018

Bibliography

DOI <https://doi.org/10.1055/a-0751-2812> |

Endoscopy International Open 2018; 06: E1406–E1409

© Georg Thieme Verlag KG Stuttgart · New York

ISSN 2364-3722

ABSTRACT

Background and study aims Colon interposition for benign strictures is associated with significant perioperative complications that carry high morbidity and mortality. Although rarely reported in the literature, adenocarcinoma can occur as a late complication in an interposed colonic segment. We report a case of a late-stage adenocarcinoma in a colonic interposition performed for benign esophageal stricture.

Introduction

Esophageal reconstruction with colon interposition after esophagectomy caused by caustic ingestion or malignant neoplasms has been standardized for almost a century [1–3]. The colon is chosen due to its size, extension, excellent blood supply, good resistance to gastric reflux and low disease incidence [1,4]. Even with a 5% to 8% mortality due to benign lesions, this type of surgery is not free from serious early or late complications, such as dehiscence of sutures leading to mediastinitis, necrosis of the anastomotic site, formation of fibrosis, and strictures [5].

Presence of malignant neoplasm in colonic interpositions post-esophagectomy is extremely rare. A review of the literature using the electronic database Medline (PubMed), reported only 11 cases (► **Table 1**), all with a common outcome, the death of the patient.

Case report

We report the case of a 63-year-old Hispanic female with a history of smoking habits (54 packs per year) and chronic obstructive pulmonary disease; she also had a previous history of squamous cell carcinoma of the cervix, cured after a total hysterectomy, 15 years earlier.

At age 33, the woman attempted suicide with caustic soda intake. Initially treated with endoscopic dilation with bougies, she remained asymptomatic for 20 years. Then, her symptoms including dysphagia and severe malnutrition (body mass index 17.1) returned, and new dilations with bougies by endoscopy were performed. However, at that, time she did not response to dilations, and after 2 years, she was referred for subtotal esophagectomy with colonic graft interposition. A colonoscopy was performed before surgery to rule out lesions. Eight years after surgery, the patient was referred to our endoscopy unit due to severe progressive dysphagia of 3 years' duration and significant weight loss (8 kilos in 2 months).

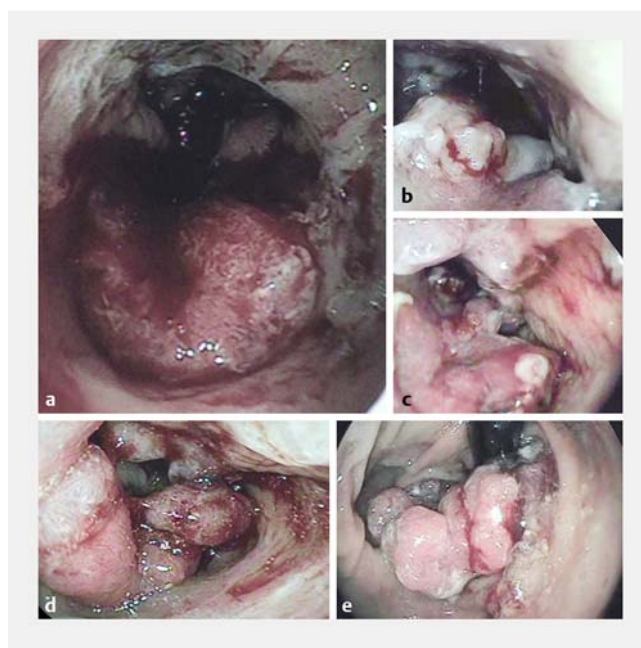
► **Table 1** Adenocarcinoma in colon interposition: literature review.

Authors	Year of publication	Surgical indication	Delay before occurrence (year)
Cheng et al. [1]	2015	Corrosive	15
Tranchart H et al. [9]	2014	Corrosive	19
Aryal MR et al. [2]	2013	Corrosive	30
Shersher DD et al. [11]	2011	Corrosive	40
Bando et al. [12]	2010	Squamous cell carcinoma	14
Sikorski et al. [10]	2010	Corrosive	44
Kuwabara et al. [13]	2009	Esophageal cancer	9
Roos et al. [6]	2007	Corrosive	40
Hsieh et al. [14]	2005	Corrosive	39
Martín et al. [7]	2005	Corrosive	14
Liau et al. [5]	2004	Esophageal cancer	30
Altorjay et al. [15]	1995	Corrosive	5
Lee et al. [16]	1994	Squamous cell carcinoma	20
Theile et al. [17]	1992	Adenocarcinoma	12
Houghton et al. [3]	1989	Corrosive	20
Haerr et al. [18]	1987	Squamous cell carcinoma	9
Licata et al. [19]	1978	Corrosive	11
Goldsmith et al. [4]	1968	Squamous cell carcinoma	2

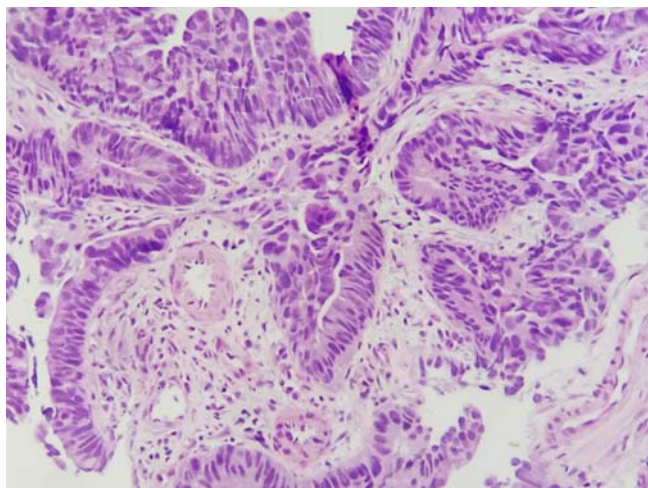
Upper gastrointestinal endoscopy (UGIE) excluded disease in the esophagus-colon anastomosis, however, an irregular, ulcerated, friable lesion, measuring 8 cm in length, causing stenosis of the organ, was diagnosed 18 cm from the incisors (► **Fig. 1**). Tissue biopsies were properly taken and anatomopathological examination showed a moderately differentiated invasive colonic adenocarcinoma (► **Fig. 2**). Computed tomography (CT) showed a colonic graft tumor and suspicious lesions in the left and right lung, which were confirmed to be metastatic after biopsy (► **Fig. 3** and ► **Fig. 4**). After a multidisciplinary meeting, a palliative approach was recommended due to the patient's poor functional status and comorbidities. She patient was started on chemotherapy and radiotherapy and died 2 months after the diagnosis.

Discussion

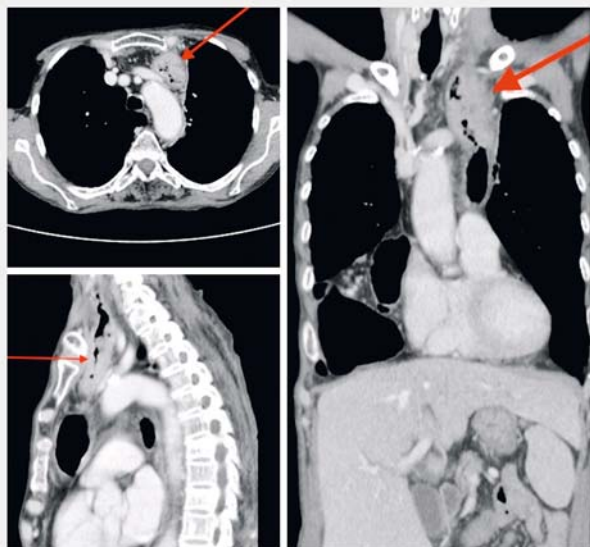
Most reported cases of esophageal cancers arising in colonic graft after esophageal surgery are due to incomplete resection of the primary tumor [3,6,7]. However, the etiopathogenesis of malignancy in postsurgical caustic stenosis is not yet fully understood [1,2]. Previous presence of polyps, colitis, chronic reflux disease and inflammation produced by food stasis are postulated etiologies for dysplastic transformation and evolution to malignant neoplasm [8]. A positive family history of colon carcinoma is also considered a risk factor [9,10].



► **Fig. 1** Upper gastrointestinal endoscopy view of the esophageal lesion. **a** Proximal portion of lesion in transposed colon. **b** Vegetative and infiltrative lesion. **c** Medial portion of lesion causing substenosis of organ lumen. **d, e** Revision of the lesion.



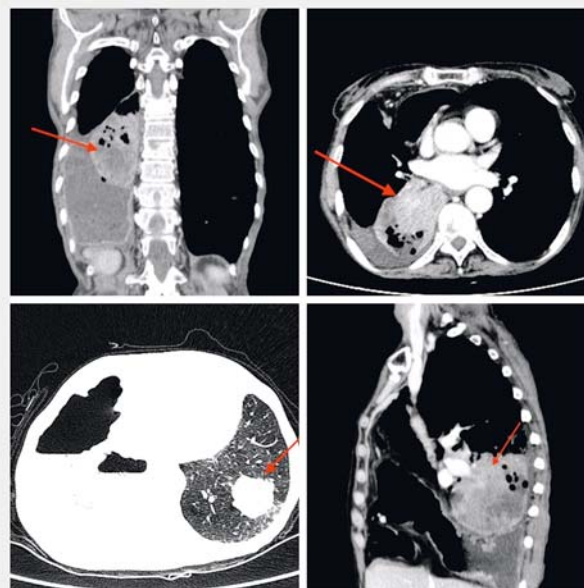
► **Fig. 2** Microscopic image with magnification of 400x. Label: Moderately differentiated invasive adenocarcinoma



► **Fig. 3** Computed tomography showing colonic graft tumor.

Patients most often present with progressive dysphagia. Respiratory symptoms due to invasion or compression have also been reported. Biopsies performed during UGIE are the gold standard for confirming the diagnosis [1, 11]. Treatment consists of complete surgical resection and might include gastric interposition, jejunal graft, and Roux-en-Y esophagojejunostomy [11]. Endoscopic resection can be curative and is recommended for early neoplasms limited to the mucosa [5, 12]. A palliative approach with radiotherapy, chemotherapy and placement of self-expanding metallic stents is possible mostly in patients whose condition is inoperable cases or who have poor functional status [1, 2, 8, 10].

There are no available guidelines for follow-up of patients with colonic transposition esophageal surgery. We believe that



► **Fig. 4** Computed tomography showing suspicious lesions in the chest.

preoperative or intraoperative colonoscopy and a follow-up with UGIE every 5 years can successfully prevent malignant lesions [1].

Conclusion

Adenocarcinoma is a very rare although possible and most often fatal late complication of colon interposition esophageal surgery. There are no available guidelines for follow-up of patients with colonic transposition esophageal surgery. More studies of this condition are needed.

Acknowledgements

We thank the patient and her family for her trust and cooperation for this case report.

Competing interests

None

References

- [1] Cheng Y-C, Wu C-C, Lee C-C et al. Adenocarcinoma of a colonic interposition graft for benign esophageal stricture in a young woman. *Endoscopy* 2015; 47: (Suppl. 01): E249–250
- [2] Aryal MR, Mainali NR, Jalota L et al. Advanced adenocarcinoma in a colonic interposition segment. *BMJ Case Rep* 2013; doi:10.1136/bcr-2013-009749
- [3] Houghton AD, Jourdan M, McColl I. Dukes A carcinoma after colonic interposition for oesophageal stricture. *Gut* 1989; 30: 880–881
- [4] Goldsmith HS, Beattie EJJ. Malignant villous tumor in a colon bypass. *Ann Surg* 1968; 167: 98–100
- [5] Liao C-T, Hsueh S, Yeow K-M. Primary adenocarcinoma arising in esophageal colon interposition: report of a case. *Hepatogastroenterology* 2004; 51: 748–749
- [6] Roos D, Busch ORC, van Lanschot JJB. Primary colon carcinoma in a colon interposition graft after oesophageal resection. *Ned Tijdschr Geneesk* 2007; 151: 2111–2114
- [7] Martin MA, Ferras A. Colon cancer: a rare complication in a colonic esophageal segment after coloesophagoplasty. *Cir Esp* 2005; 77: 46–47
- [8] Ribeiro IB, Bernardo WM, Martins C et al. Colonic stent versus emergency surgery as treatment of malignant colonic obstruction in the palliative setting: a systematic review and meta-analysis. *Endosc Int Open* 2018; 5: 1–10
- [9] Tranchart H, Chirica M, Munoz-Bongrand N et al. Adenocarcinoma on colon interposition for corrosive esophageal injury: case report and review of literature. *J Gastrointest Cancer* 2014; 45: (Suppl. 01): 205–207
- [10] Sikorszki L, Horvath OP, Papp A et al. Colon cancer after colon interposition for oesophageal replacement. *Magy Seb* 2010; 63: 157–160
- [11] Shersher DD, Hong E, Warren W et al. Adenocarcinoma in a 40-year-old colonic interposition treated with Ivor Lewis esophagectomy and esophagogastric anastomosis. *Ann Thorac Surg* 2011; 92: e113–e114
- [12] Bando H, Ikematsu H, Fu K-I et al. A laterally-spreading tumor in a colonic interposition treated by endoscopic submucosal dissection. *World J Gastroenterol* 2010; 16: 392–394
- [13] Kuwabara Y, Kimura M, Mitsui A et al. Adenocarcinoma arising in a colonic interposition following a total gastrectomy: report of a case. *Surg Today* 2009; 39: 800–802
- [14] Hsieh Y-S, Huang K-M, Chen T-J et al. Metachronous adenocarcinoma occurring at an esophageal colon graft. *J Formos Med Assoc* 2005; 104: 436–440
- [15] Altorjay A, Kiss J, Voros A et al. Malignant tumor developed in colon-esophagus. *Hepatogastroenterology* 1995; 42: 797–799
- [16] Lee SJ, Koay CB, Thompson H et al. Adenocarcinoma arising in an oesophageal colonic interposition graft. *J Laryngol Otol* 1994; 108: 80–83
- [17] Theile DE, Smithers BM, Strong RW et al. Primary adenocarcinoma in a colonic „oesophageal“ segment. *Aust N Z J Surg* 1992; 62: 158–160
- [18] Haerr RW, Higgins EM, Seymore CH et al. Adenocarcinoma arising in a colonic interposition following resection of squamous cell esophageal cancer. *Cancer* 1987; 60: 2304–2307
- [19] Licata AA, Fecanin P, Glowitz R. Metastatic adenocarcinoma from oesophageal colonic interposition. *Lancet (London, England)* 1978; 1: 285