

Lateral exposure of the proximal and distal peroneal artery without bone resection

Andre Brito-Queiroz, PhD, MD,^a Rodrigo de Sousa Mota, MD,^a Bruno Rodrigues Barros, MD,^a Tayrine Mazotti de Moraes, MD,^b Grace Carvajal Mulatti, MD, PhD,^b and José Siqueira de Araújo Filho, MD,^a Salvador and São Paulo, Brazil

ABSTRACT

Surgical revascularization with distal bypass surgery is associated with good outcomes for chronic limb-threatening ischemia. The peroneal artery, the most-often preserved outflow vessel, is commonly reached through a lateral approach involving resection of the fibula. We present two different techniques for a lateral approach to the peroneal artery: the first by proximal exposure and the second by exposing the distal segment of the peroneal artery. Both techniques are performed without bone resection. (J Vasc Surg Cases Innov Tech 2023;9:101144.)

Key words: Bypass surgery; Chronic limb-threatening ischemia; Fibula resection; Peripheral artery disease; Peroneal artery

Approaching the peroneal artery has been a challenge for vascular surgeons for many years. Its deep position, surrounded by muscles and interosseous membrane, in addition to its position between the tibia and fibula, makes this the most difficult vessel for lower limb revascularization. Although many techniques have been described for peroneal artery access, most have involved large incisions, dissection, and fibula resection.^{1,2}

The position of the peroneal artery in relation to the fibula and surrounding structures differs between its proximal and distal portions. The proximal peroneal artery is slightly posterior and medial to the fibula, and the distal segment is more anterior, between the tibia and fibula and immediately beneath the interosseous membrane.

In 2014, De Luccia et al³ described a technique for lateral and posterior access to the proximal peroneal artery. Distal lateral access, first described by Archie⁴ in 1987, involves dissection medial to the fibula, followed by opening the interosseous membrane. The objective of the present report is to describe two less-invasive techniques for proximal and distal lateral exposure of the peroneal artery that do not require fibular resection. The patients provided written informed consent for the report of their case details and imaging studies.

SURGICAL TECHNIQUE

Although the techniques we present were developed for lower limb revascularization in chronic limb-threatening ischemia (CLTI), they can be used to treat trauma or any other situation requiring access to the peroneal artery. The peroneal artery is commonly used as a distal target vessel, although some investigators have demonstrated that this vessel can be used as an inflow artery for inframalleolar bypass.⁵

Our first choice for the conduit is a nonreversed ipsilateral great saphenous vein, and valvulotomy is performed using a Mills valvulotome. However, other techniques and conduits, such as the lesser saphenous vein or arm veins, can also be used. The inflow artery must be selected according to the diagnostic imaging findings and individualized according to the patient.

PROXIMAL EXPOSURE

The position of the surgeon and patient is essential for better visualization and ergonomics. The surgeon should be seated on the same side as the affected limb with their eyes at the skin incision level. The patient should be placed in the supine position with the knee flexed to approximately 90°. An assistant positioned on the other side of the patient should gently pull the knee toward the assistant to cause partial rotation and adduction. The assistant should also support the foot, preventing it from moving to avoid knee extension.

A longitudinal 4-cm skin incision is adequate for exposure. This incision should be 1 cm posterior to the fibula and should be in the middle third of the leg and deepened through the subcutaneous tissue and fascial plane (Fig 1). The initial direction of dissection should be toward the lateral aspect of the fibula. The bone can be reached through an avascular plane posterior to the soleus and anterior to the peroneus longus. The lateral face of the fibula can also be reached through division of the soleus muscle.

From the Hospital Ana Nery, Universidade Federal da Bahia, Salvador^a; and the Hospital das Clínicas, São Paulo University, São Paulo.^b

Author conflict of interest: none.

Correspondence: Andre Brito-Queiroz, PhD, MD, Department of Vascular and Endovascular Surgery, Hospital Ana Nery, Universidade Federal da Bahia, Saldanha Marinho St, S/N, Salvador, Bahia 40301-155, Brazil (e-mail: andrebrito01@hotmail.com).

The editors and reviewers of this article have no relevant financial relationships to disclose per the Journal policy that requires reviewers to decline review of any manuscript for which they may have a conflict of interest.

2468-4287

© 2023 The Author(s). Published by Elsevier Inc. on behalf of Society for Vascular Surgery. This is an open access article under the CC BY-NC-ND license (<http://creativecommons.org/licenses/by-nc-nd/4.0/>).

<https://doi.org/10.1016/j.jvscit.2023.101144>

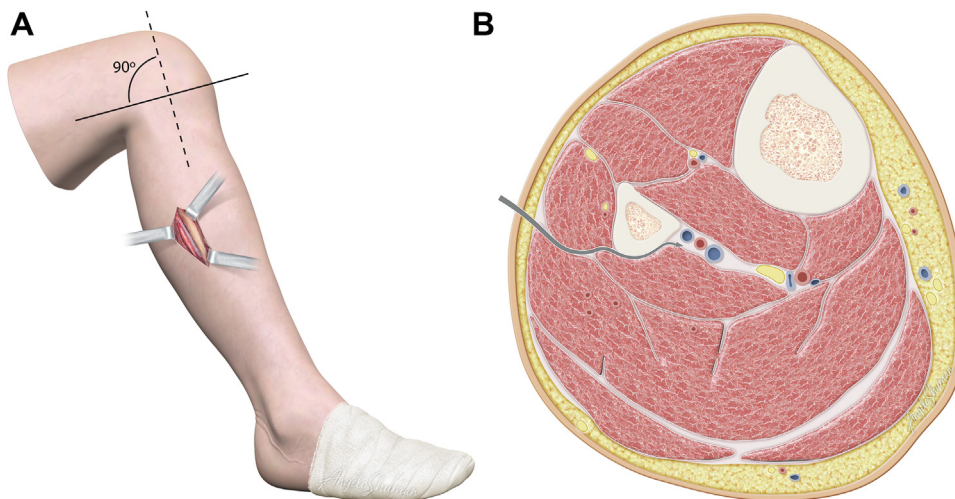


Fig 1. Illustration showing proximal exposure of the peroneal artery (A) and the path to the artery (arrow) in the axial plane (B).

The insertion of the flexor hallucis longus muscle on the posterior surface of the fibula should be carefully released using electrocautery, and the vascular bundle should appear just posterior and medial to the fibula (Fig 1). In this step, a Langenbeck retractor is placed in the posterior region of the incision and used to pull the soleus and flexor hallucis longus muscles, resulting in posterior traction of the peroneal vessels, moving them away from the fibula and providing better exposure (Fig 2).

The peroneal artery should be carefully dissected from the peroneal veins, avoiding venous lesions that could cause accidental bleeding and delay the procedure. Minimal dissection is performed to enable artery visualization and distal anastomosis. The tunnel should extend from the popliteal fossa to the exposed peroneal artery through a subfascial plane. From the popliteal fossa to the inflow artery, the tunnel can be the same as that used for other revascularizations in this area.

DISTAL EXPOSURE

The patient is placed in the supine position with the knee flexed to $\sim 30^\circ$. In the distal one third of the leg, a longitudinal skin incision (~ 4 cm) is made in the projection of the anterior edge of the fibula, generally 2 to 3 cm lateral to the anterior border of the tibia (Fig 3). The incision is deepened through the subcutaneous tissue and fascia, entering the anterior compartment.

At this point, the extensor digitorum longus muscle is reflected medially, exposing the interosseous membrane. The membrane is opened longitudinally close to the fibula, with the terminal peroneal vascular bundle quickly identified just below it (Fig 4). Care must be taken to isolate the artery from the veins to minimize bleeding. A single vessel loop can be used to gently bring the peroneal artery to a more superficial position.

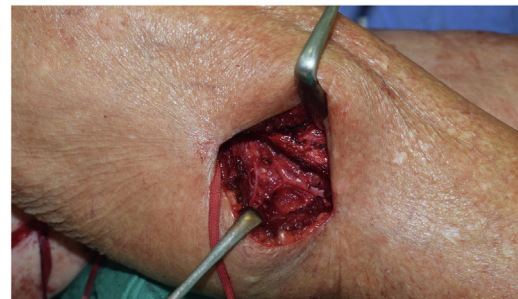


Fig 2. Photograph showing proximal peroneal artery exposure.

The tunnel should be similar to a bypass to the distal anterior tibial artery. We generally cross the interosseous membrane proximally and tunnel through the anterior compartment to the exposed segment of the peroneal artery.

For both exposure types, we normally avoid using clamps during the distal anastomosis, because they occupy space in the surgical field and can damage calcified arteries. We prefer to use Esmarch bandages to control bleeding; however, silicone vessel loops can also be used safely.⁶ Anastomosis is performed with a Castroviejo needle holder and surgical loupes. Completion angiography is routinely performed to ensure good outflow, a permeable anastomosis, and proper positioning of the conduit.

DISCUSSION

In recent years, many new devices and technical skills have made the endovascular approach for CLTI more widespread. However, open distal revascularization, especially using the great saphenous vein, has proved

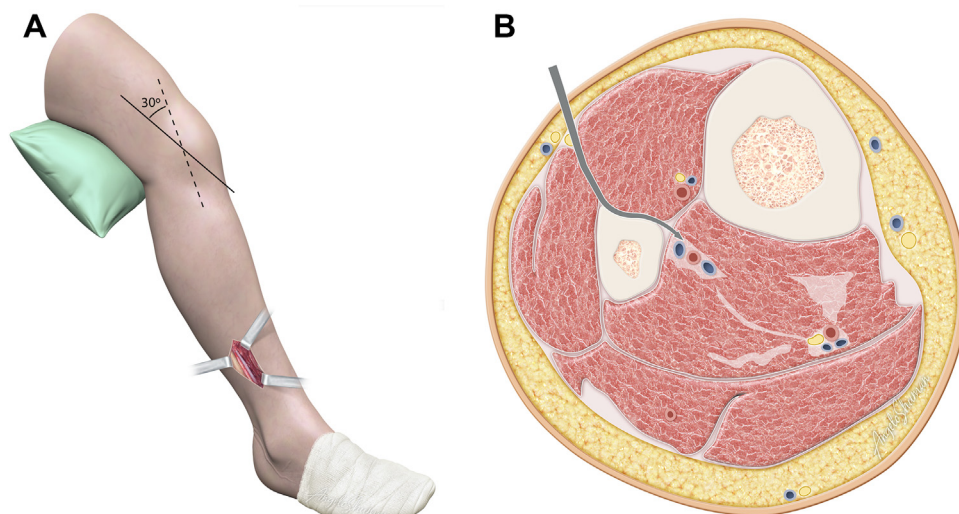


Fig 3. Illustration showing distal exposure of the peroneal artery (**A**) and the path to the artery (arrow) in the axial plane (**B**).

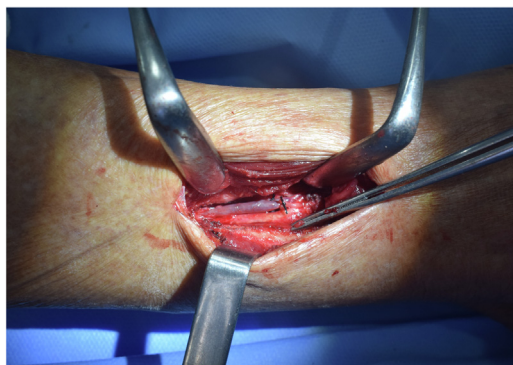


Fig 4. Photograph showing distal peroneal artery exposure.

to be a long-lasting technique with good outcomes in terms of mortality and limb salvage.⁷

Peroneal bypass for limb salvage in patients with CLTI is not a new concept, and the most widespread peroneal artery exposure techniques have not changed for almost one century.¹ These techniques include the medial approach, which is the most frequently used, and the lateral approach through fibula resection.

De Luccia et al³ described a method of lateral access to the peroneal artery without resecting the fibula. This technique is easily replicated using the steps they described. It has become the first choice by our group when the target is the peroneal artery, and we call it “De Luccia’s access” in reference to the author. One limitation of their technique is the approach to the distal segment of the peroneal artery because this segment is not accessible through a lateral approach posterior to the fibula.

The distal segment of the peroneal artery is closer to the anterior edge of the fibula and is immediately beneath the interosseous membrane. Access to the distal portion of the artery can be essential when the proximal peroneal artery is completely occluded or diseased. The technique for the distal approach was first demonstrated by Archie⁴ and was reproduced and described in greater detail by Slim et al⁵ and Ichikawa et al.⁸

These techniques require technical refinement and detailed anatomic knowledge. They can result in less-invasive operations, enabling faster recovery and reducing sequelae. Although it is the most commonly used approach for distal access of the peroneal artery, lateral access with partial fibular resection can increase stress on the tibia and, as previously demonstrated, could predispose patients to tibial fracture, especially older women with osteoporosis.⁹

Despite the widespread adoption of endovascular techniques, recent data have shown that lower limb revascularization surgery can have excellent results in CLTI patients. Training and experience with both techniques is essential to provide more effective treatment for patients with CLTI.

CONCLUSIONS

Open surgery remains an important option for lower limb salvage. Surgical training and anatomic knowledge are essential to determining the best approach for each patient. Despite important endovascular progress, there is also room for innovation and improvement in open techniques.

REFERENCES

1. Elkin DC, Kelly RP. Arteriovenous aneurysm: exposure of the tibial and peroneal vessels by resection of the fibula. *Ann Surg* 1945;122:529-45.

2. Ouriel K. The posterior approach to popliteal-crural bypass. *J Vasc Surg* 1994;19:74-9.
3. De Luccia N, Queiroz AB, Mulatti CC, Ferreira Espírito Santo FR, Sasaki Neto PI, Schneidwind KD. Lateral approach to the peroneal artery without resection of the fibula for lower limb revascularization. *J Vasc Surg* 2014;59:857-9.
4. Archie JP Jr. Anterior compartment exposure of the distal peroneal artery for bypass grafting. *Tex Heart Inst J* 1987;14:297-9.
5. Slim H, Pran L, Zyada RWA, Valenti D, Rashid H. Novel technique for Latero-anterior approach to the terminal peroneal artery for bypass surgery without fibular resection. *Ann Vasc Surg* 2021;72: 637-42.
6. Shindo S, Iyori K, Kobayashi M, et al. Nondissection method for tibial bypass surgery using Esmarch's rubber bandage or an automatic sequential pneumatic tourniquet: long-term results. *Cardiovasc Surg* 1998;6:27-33.
7. Farber A, Menard MT, Conte MS, Kaufman JA, Powell RJ, Choudhry NK; BEST-CLI Investigators. Surgery or endovascular therapy for chronic limb-threatening ischemia. *N Engl J Med* 2022;387:2305-16.
8. Ichikawa Y, Kikuchi S, Yoshida Y, Uchida D, Koya A, Azuma N. Lateral approach to distal peroneal artery without fibular resection. *J Vasc Surg Cases Innov Tech* 2022;8:362-6.
9. Kahn MB, Profeta B, Hume E, Leichter R, Carabasi RA, DiMuzio PJ. Tibia fracture after fibula resection for distal peroneal bypass. *J Vasc Surg* 2001;34:979-82.

Submitted Dec 28, 2022; accepted Feb 14, 2023.